



Whole-body skeletal muscle assessment using lower extremity CT images.

Sotaro Kono¹, Keisuke Uemura², Mazen Soufi³, Makoto Iwasa⁴, Kazuma Takashima¹, Hidetoshi Hamada², Yoshito Otake³, Yoshinobu Sato³, Seiji Okada¹, Nobuhiko Sugano²

¹ Department of Orthopaedics, Osaka University Graduate School of Medicine

² Department of Orthopaedic Medical Engineering, Osaka University Graduate School of Medicine

³ Division of Information Science, Graduate School of Science and Technology, Nara Institute of Science and Technology

⁴ Division of Orthopedic Surgery, National Hospital Organization Osaka National Hospital

Abstract

Assessment of the loss in skeletal muscle mass (SMM) is often quantified by measuring the skeletal muscle index (SMI) through dual-energy x-ray absorptiometry (DXA). However, as SMI measurement is not always performed in the clinical setting, we aimed to develop and verify a system that predicts SMM loss from the CT images of the lower extremity that were acquired for the preoperative assessment of hip surgery.

Sixty female patients with hip diseases who underwent CT and a whole-body DXA scan were retrospectively analyzed. Using an automated CT segmentation model of each muscle, muscles of the lower extremities were segmented and classified into three groups: gluteal muscles, muscles above the knee joint, and all lower extremity muscles. The relationship between the total muscle mass of the three groups and DXA-measured lean mass was assessed. Further, the SMI of the three groups was calculated, and their diagnostic performance in predicting sarcopenia ($SMI < 5.4 \text{ kg/m}^2$) was evaluated using the receiver operating characteristic curve (ROC) analysis.

Strong correlations were observed with lean mass and SMM of gluteal muscles ($r = 0.82$, $p < 0.01$), above the knee joint ($r = 0.90$, $p < 0.01$), and of all lower extremities ($r = 0.94$, $p < 0.01$). The area under the curves for each region were 0.93, 0.90, and 0.96, respectively.

Our findings suggest that lower extremity CT scans with limited regions of interest may serve as a viable method for predicting whole-body SMM loss, indicating the possibility of diagnosing sarcopenia from such CT images.

1 Introduction

There is an increasing demand to evaluate skeletal muscle mass (SMM) for older people, as studies have shown a loss in SMM leads to a decrease in activities of daily living. Often, loss in SMM is quantified and evaluated by measuring the skeletal muscle index (SMI), calculated by dividing the SMM of the extremities (in grams) by the square of body height. SMI can be quantified by dual-energy x-ray absorptiometry (DXA) or bioelectrical impedance analysis (BIA). Previous reports have shown the cut-off value to diagnose the excessive loss in SMI, which is defined as ‘sarcopenia’. For example, a cutoff value of 5.4 kg/m^2 (women) and 7.0 kg/m^2 (men) in SMI has been established for Asian people in the 2014 AWGS Consensus [1, 2].

While the necessity and importance of evaluating the SMI have been widely acknowledged, the measurement of SMI is only sometimes carried out in the actual clinical settings as equipment (DXA or BIA) is limited, leaving the loss in SMM often unevaluated and untreated. Thus, it would be clinically meaningful to screen for the loss in SMM using the images acquired for clinical investigation (i.e., opportunistic screening). To this end, we aimed in this study to develop and validate a method that quantifies SMI from CT images acquired for the preoperative assessment of hip joint diseases. As hip CT scans have limited field of view (FOV), the effect of FOV on the accuracy of evaluating the SMI was also evaluated.

2 Material and methods

Sixty patients (all women, mean age: 59.9 ± 20.1 years) who underwent hip surgery were analyzed in this study. For these patients, a CT scan was acquired from the pelvic brim to the ankle, and a whole-body DXA was acquired. First, each skeletal muscle in the lower extremities was automatically segmented from the CT images using a Bayesian U-net, a deep-learning model for semantic segmentation that we have previously developed [3]. Then, the segmented labels were used to measure the volume and density of each muscle to calculate the SMM (in grams) of each muscle. The psoas muscle was excluded as the whole muscle was not included in the imaging range. Muscles of the lower extremity were classified into three groups: the gluteal muscles group, the muscles above the knee joint, and muscles of all lower extremities (Figure 1), and SMM of these groups was defined as SMM_Glu, SMM_AK, SMM_all, respectively. The relationship between the SMM of these three groups and the lean mass of the lower extremity measured using DXA (LM_DXA) was clarified using Spearman’s correlation coefficient. Then, the SMM of each group was calculated into SMI and was defined as SMI_Glu, SMI_AK, and SMI_all, respectively. Finally, receiver operating characteristic (ROC) curve analysis was performed to clarify the diagnostic performance of the three SMIs in detecting whole-body SMM loss for women (i.e., $\text{SMI} < 5.4 \text{ kg/m}^2$) obtained from DXA. The area under the curve (AUC) was calculated and compared across the SMI groups. All analyses were performed automatically using MATLAB (R2022a), and $p < 0.05$ was considered statistically significant.

3 Results

LM_DXA, SMM_Glu, SMM_AK, and SMM_all were $5529 \pm 845\text{g}$, $907 \pm 170\text{g}$, $3261 \pm 621\text{g}$, and $4342 \pm 772\text{g}$, respectively. In the correlation analysis, correlation between LM_DXA was $r = 0.82$, 0.90 , and 0.94 for the SMM_Glu, SMM_AK, and SMM_all, respectively (all $p < 0.01$). In the ROC analysis, the AUCs for diagnosing whole-body SMM loss using SMI_Glu, SMI_AK, and SMI_all were 0.93 , 0.90 , and 0.96 , respectively (Figure 2) (all $p > 0.05$).

4 Discussion

In this study, the SMM of the lower extremities was measured from CT scans and was compared to the lean mass measured by DXA. There was a strong correlation between SMM of the lower extremity and LM_DXA. The strongest correlation was found between SMM_all ($r = 0.94$), which supported the fact that the SMM quantification method applied in this study is in line with the SMM prediction in DXA [4, 5].

Some previous reports have correlated the SMM of the lower extremity with whole-body SMM and indicated the potential for using the SMM of the lower extremity in predicting the whole-body SMM [6, 7, 8]. However, limited information has been provided on whether a loss in the SMM of the extremities (i.e., loss in SMI) can be predicted from CT images. Our study revealed that loss in SMI can be accurately predicted with an AUC > 0.9 from the SMIs of the lower extremity, even when only the gluteal muscles were included in the FOV of the CT images. As the FOV of the abdominal CT images is usually around the lesser trochanter, our results indicate the potential of abdominal CT images being used to screen for sarcopenia.

5 Conclusions

Our study showed that SMM can be accurately measured from CT images of the lower extremities and showed the possibility of CT scans being used to detect loss in SMI. As $SMI < 5.4\text{kg/m}^2$ was accurately predicted from CT images that only included the proximal region of the femur, our study indicates the potential of CT images being used for diagnosing sarcopenia. It would be interesting for future studies to apply our findings to abdominal CT images so that sarcopenia could be efficiently screened for patients who undergo abdominal CT scans.

References

1. Chen, L.-K., Liu, L.-K., Woo, J., Assantachai, P., Auyeung, T.-W., Bahyah, K. S., Chou, M.-Y., Chen, L.-Y., Hsu, P.-S., Krairit, O., Lee, J. S. W., Lee, W.-J., Lee, Y., Liang, C.-K., Limpawattana, P., Lin, C.-S., Peng, L.-N., Satake, S., Suzuki, T., ... Arai, H. (2014). Sarcopenia in Asia: Consensus Report of the Asian Working Group for Sarcopenia. *Journal of the American Medical Directors Association*, 15(2), 95–101. <https://doi.org/10.1016/j.jamda.2013.11.025>
2. Chen, L.-K., Woo, J., Assantachai, P., Auyeung, T.-W., Chou, M.-Y., Iijima, K., Jang, H. C., Kang, L., Kim, M., Kim, S., Kojima, T., Kuzuya, M., Lee, J. S. W., Lee, S. Y., Lee, W.-J., Lee, Y., Liang, C.-K., Lim, J.-Y., Lim, W. S., ... Arai, H. (2020). Asian Working Group for Sarcopenia: 2019 Consensus Update on Sarcopenia Diagnosis and Treatment. *Journal of the American Medical Directors Association*, 21(3), 300-307.e2. <https://doi.org/10.1016/j.jamda.2019.12.012>
3. Fuchs, C. J., Kuipers, R., Rombouts, J. A., Brouwers, K., Schrauwen-Hinderling, V. B., Wildberger, J. E., Verdijk, L. B., & Van Loon, L. J. C. (2023). Thigh muscles are more susceptible to age-related muscle loss when compared to lower leg and pelvic muscles. *Experimental Gerontology*, 175, 112159. <https://doi.org/10.1016/j.exger.2023.112159>
4. Hiasa Y, Otake Y, Takao M, et al (2020) Automated Muscle Segmentation from Clinical CT Using Bayesian U-Net for Personalized Musculoskeletal Modeling. *IEEE Trans Med Imaging* 39:1030–1040. <https://doi.org/10.1109/TMI.2019.2940555>

5. Jung Lee, S., Janssen, I., Heymsfield, S. B., & Ross, R. (2004). Relation between whole-body and regional measures of human skeletal muscle. *The American Journal of Clinical Nutrition*, 80(5), 1215–1221. <https://doi.org/10.1093/ajcn/80.5.1215>
6. Mizuno, T., Matsui, Y., Tomida, M., Suzuki, Y., Ishizuka, S., Watanabe, T., Takemura, M., Nishita, Y., Tange, C., Shimokata, H., Imagama, S., Otsuka, R., & Arai, H. (2023). Relationship between quadriceps muscle computed tomography measurement and motor function, muscle mass, and sarcopenia diagnosis. *Frontiers in Endocrinology*, 14, 1259350. <https://doi.org/10.3389/fendo.2023.1259350>
7. Schweitzer, L., Geisler, C., Pourhassan, M., Braun, W., Glüer, C.-C., Bosy-Westphal, A., & Müller, M. J. (2015). What is the best reference site for a single MRI slice to assess whole-body skeletal muscle and adipose tissue volumes in healthy adults? *The American Journal of Clinical Nutrition*, 102(1), 58–65. <https://doi.org/10.3945/ajcn.115.111203>
8. Yoo, H. J., Kim, Y. J., Hong, H., Hong, S. H., Chae, H. D., & Choi, J.-Y. (2022). Deep learning-based fully automated body composition analysis of thigh CT: Comparison with DXA measurement. *European Radiology*, 32(11), 7601–7611. <https://doi.org/10.1007/s00330-022-08770-y>

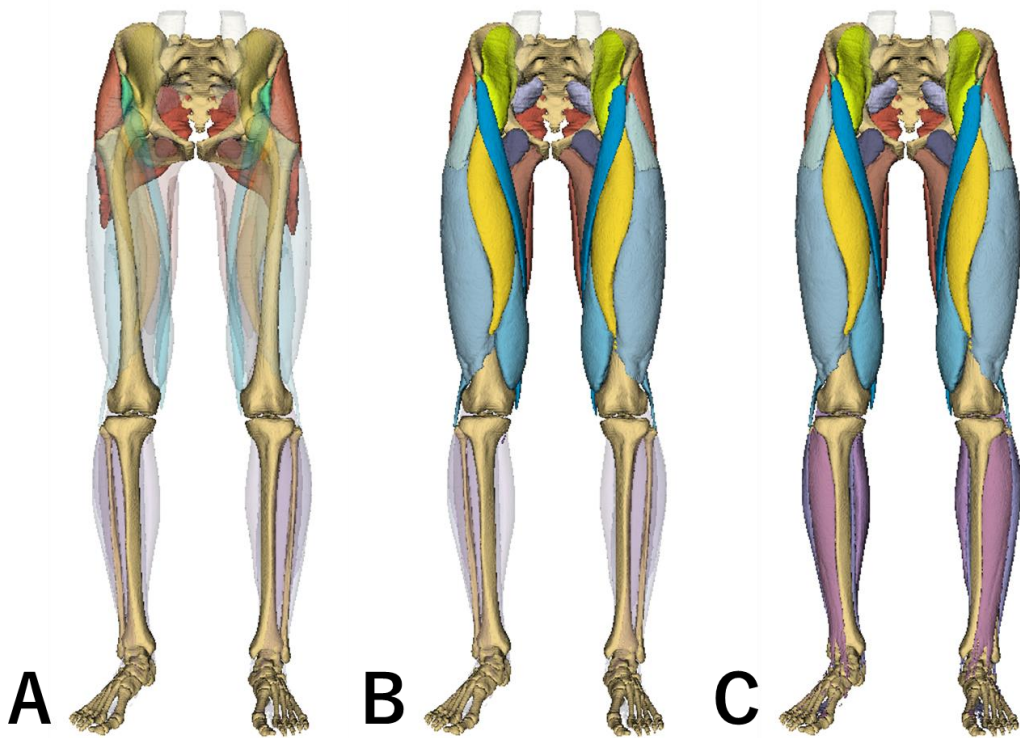


Figure 1 The 3D models of the musculoskeletal system in the lower extremities (A) The Gluteal muscle group (B) Muscle group above the knee joint (C) all muscles in the lower extremity.

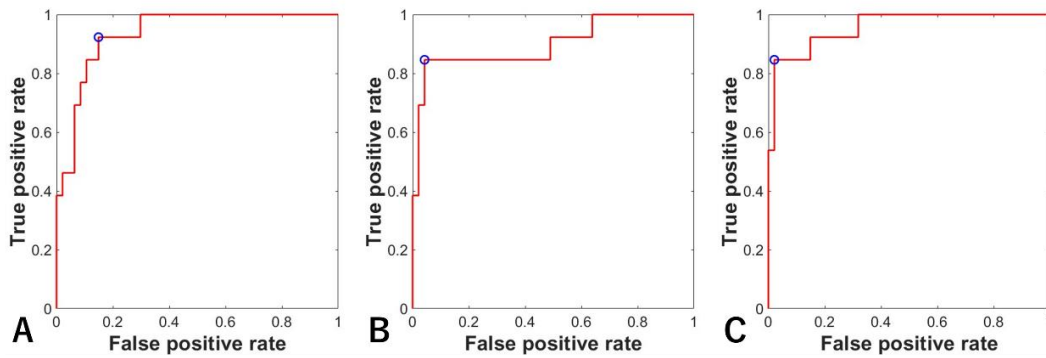


Figure 2 ROC curve for predicting SMM loss using (A) SMI_Glu (B) SMI_AK (C) SMI_all. The blue circle indicates the optimal cut-off point.