



Deep Learning for MRI-Based Brain Tumor Identification and Classification

D Jareena Begum, Sp. Chokkalingam and
B. Sundaravadivazhagan

EasyChair preprints are intended for rapid dissemination of research results and are integrated with the rest of EasyChair.

December 16, 2023

Deep Learning for MRI-Based Brain Tumor Identification and Classification

D Jareena Begum ¹[0000-1111-2222-3333] and Dr. SP. Chokkalingam ²[1111-2222-3333-4444]
Dr.B.Sundaravadivazhagan³

¹ Research Scholar, Department of Computer Science and Engineering, Amrita School of Computing, Chennai, Amrita Vishwa Vidyapeetham, India.

² Professor, Department of Computer Science and Engineering, Amrita School of Computing, Chennai, Amrita Vishwa Vidyapeetham, India.

³Department of information technology, University of Technology and Applied Sciences University of Technology and Applied Sciences, Al Mussana, Oman

¹dj_begum@ch.students.amrita.edu

²sp_chokkalingam@ch.amrita.edu

³bsundaravadivazhagan@gmail.com

Abstract. Radiology tumour spotting is complicated and requires medical knowledge. Thus, lack of doctors should not delay cancer detection programmes. Biomedical image processing software helps find brain tumours in MRI data. This study segmented and detected brain tumours using MRI sequence images. This process is complicated by the similarity of normal tissues and the wide range of tumour tissues in different patients. Brain tumour detection is the main goal. Brain tumour diagnosis requires precise tumour size and position. This paper presents a deep learning-based brain tumour MRI segmentation and classification method. We preprocessed the photos with the Gaussian blur filter and image enhancement tool. Binary thresholding segments. Morphological methods reveal traits. CNN will assess brain MRI regularity. This study uses Kaggle Dataset. We train with 255 brain MRIs, 155 with tumours and 98 normal, and achieve 97% accuracy. We test the model using Kaggle brain MR datasets. Brain tumour detection, segmentation, and categorization; medical image processing. This study proposed an easy-to-implement way for identifying and classifying bone tumours.

Keywords: Brain tumor, Segmentation, Extraction MRI Imaging Feature, CNN.

I. INTRODUCTION

Brief summary [1-3]. The central nervous system sends sensory data and reactions throughout the body. This requires brain-spinal nerve cooperation.

The brain stem, cerebral cortex, and cerebellum have distinct roles. Adult brains weigh 1.2 to 1.4 kilogrammes and measure 1260 to 1130 cubic millimetres

[5]. Decision-making, motor control, and problem-solving involve the frontal lobe. Parietal cortex controls body direction. The temporal lobe remembers and perceives, while the occipital analyses visual information. Cerebral cortex neurons make the brain's outermost layer [6]. The cerebellum is smaller than the brain lobe. Motor control regulates voluntary movements in nervous-systemed animals. Due to stroke size and territory, ALI, lesionGnb, and LINDA fail to detect the small lesion area. Human cerebellums are well-organized [7]. Cerebellum areas include anterior, posterior, and flocculonodular. The anterior-posterior vermis is circular. The cerebellum has a grey brain and a WM core. Cerebellum cortex is slightly smaller than frontal lobe cortex. Your front and back heads govern your physical skills [4, 8]. Flocculonodular area maintains homeostasis. The brain stem is a 7–10-centimetre tube. It regulates breathing, balance, and eye movement with central and peripheral nerve bundles. The thalamus sends nerves down the spinal column through the brain stem. They then expand throughout the body. The main brain stem parts are the pons, medulla, and midbrain. Motor control, auditory understanding, and vision are controlled by the midbrain. The pons regulates breathing, intra-brain contact, and feelings, while the medulla oblongata controls blood pressure, digestion, and sneezing. Stroke tumours.

[2, 10] Brain tumours spread slowly or rapidly. Benign cancer does not spread. The WHO classifies brain tumours I–IV. Grade I and II tumours grow slowly, while grade III and IV tumours grow quickly and have a worse prognosis [10]. Thus, a brain tumour severity scale:

Slow-growing, non-metastatic tumours. Surgery can nearly eliminate these, which raise long-term mortality. This cancer is pilocytic astrocytoma, type 1.

Grade II tumours grow slowly but can spread. Tumors can return after surgery. Oligodendroglioma is an example.

Grade III tumours are tissue-invasive and fast-growing. These tumours require radiation or treatment after surgery. This describes anaplastic astrocytoma.

Grade IV tumours spread rapidly and are the most dangerous. They may expand quickly using blood vessels. Including glioblastoma multiforme Sudden blood clot-forming stroke:

Stroke is the main cause of adult disability and death Brain blood flow interruption causes tissue hypoxia and death within hours. Stroke lesions are acute, subacute, or permanent.

1.1 VIEWING BRAINS

Brain tumour patients often undergo PET, CT, DWI, and MRI brain structure analysis.

1.2. PET SCANS

PET uses unique radioactive tracers. PET can analyse metabolic brain tumour traits like glucose metabolism, lipid synthesis, oxygen use, and amino acid metabolism. Fluorodeoxyglucose (FDG), the nuclear medicine gold standard, makes it one of the most effective metabolic methods. FDG is a common PET brain marker. FDG-PET images cannot distinguish radiation necrosis from recurring high-grade (HG) tumours, Radioactive tracers used in PET scans can hurt the body and cause an allergic

reaction. Iodine and aspartame allergies exist. PET tracers can't identify anatomical structures either because their spatial precision is lower than an MRI scan.

1.3. CGI

CT exams reveal more than X-rays. CT scans have been popular since their invention. According to research , the US performs 62 million CT scans yearly, 4 million of which are on children. CT scans show organs, bones, blood systems, and other body parts. Regular X-rays use less radiation. Multiple CT exams may cause cancer due to radiation exposure. CT radiation exposures are used to determine cancer risks . MRI can assess components that CT scan could not .

1.4 MRI

MRI scans can detect brain abnormalities earlier than other imaging methods and rapidly assess many body parts . Brain anatomy makes tumour separation difficult .This work covers preprocessing, segmentation, feature extraction, reduction, classification, and deep learning. Performance metrics and standard data sets conclude.

1.5 DIFFUSION SCALING IMAGING

MRI sequences can determine stroke lesion age, location, and extent . Computerized disease progression rate diagnosis may improve treatment choices . Cognitive neuroscience researchers studied brain injury and mental disability 123 times. 8:3161–3183 Complex Cognitive Systems (2022) 3163 Fig. 1 Segmenting stroke lesions helps treat brain tumour detection datasets by studying the full infected brain . Stroke lesions change over time, making segmentation tough. DWI and FLAIR MRI scans detect stroke lesions. DWI finds the infection as a hyperintense area during stroke onset. Hypoperfusion reveals the perfusion map. Penumbra tissue is between two other areas. Stroke lesions occur in many body locations. These tumours are irregular and non-vascular. Multiple lesions can occur. Stroke-related tumours are millimeter-scale and hemisphere-wide. Even within a hotspot, each hemisphere's structure and disease severity vary. Because white matter hyper intensities and chronic stroke lesions look alike, automated stroke segmentation is difficult .

Brain tumours are deadly because the brain is the most complex organ. Malignant cells form brain tumours. A small rise in brain cell size, protected by a hard cranium, can cause severe pain and death. Is brain cancer benign? (noncancerous). Inflammation—whether benign or malignant—can raise cerebral pressure. It may kill or permanently damage the brain. Brain tumours have two categories: Primary and tertiary tumours exist. Internal brain tumours are main. Dangerous and mild primary tumours are equally common. Metastatic brain tumours are secondary cancers that expand to the brain. It occurs when cancerous cells from other organs reach the brain. All secondary brain tumours are malignant. Benign tumours never metastasize.

An effective treatment strategy that begins with a precise diagnosis of brain tumours is essential for reducing potentially fatal side effects. Imaging is vital in identifying brain lesions for diagnosis. In this thesis, magnetic resonance imaging (MRI) data is utilised due to the supremacy of MRIs over CT images in the diagnosis of brain tumours and the greater detail they show. Once a brain scan image is received, it is

vital to precisely identify the tumor's size and position. This is important for the neurosurgeon to make a full evaluation. Radiologists use magnetic resonance imaging (MRI) to photograph internal human structures and processes. Sagittal, coronal, and axial views of the skeleton are presented, which aids in comprehending the structure of the body [1].

II. LITERATURE SURVEY

Using Neural Learning Techniques A 16-layer VGG-16 deep NN was introduced by B. Srikanth et al. [22], which takes enhanced images from a pre-processing phase and sends them to a convolution layer for feature extraction and downsampling (Convolution, ReLU, MaxPooling). When applied to MR images of brain tumours, their technique significantly boosted the accuracy of multiple classifications. Overfitting is prevented by the SoftMax and fully-linked layers. After 20 rounds of training, their model achieves a maximum of 98% precision.

According to Tandel et al. Five clinical multiclass datasets were produced by him. Brain tumour categorization was enhanced using MRI images and a Convolutional Neural Network (CCN) trained with transfer learning. Several other classification strategies were tested against CNN, including Decision Trees, Naive Bayeses, Linear Discrimination, K-Nearest Neighbors, and Support Vector Machines (SVM). On five different multiclass classification brain tumour datasets, the CNN-based (DL) model achieved better results than six machine learning model techniques. After being subjected to K2, K5, and K10 cross-validation, the CNN-based AlexNet achieved mean accuracy values of 87.14, 93.74, 95.97, 96.65, and 100% across five classes, respectively.

In [15], a CNN technique was used to categorise gliomas, meningiomas, and pituitary adenomas. Features from a brain MRI were extracted by a GoogleNet that had already been trained. Extract features using proven classifications. The proposed method has a higher classification accuracy than any other method. Accuracy, F-score, recall, specificity, and AUC were all evaluated. Evidence suggests that transfer learning is effective in situations where there is a dearth of medical images.

proposed using a deep origin residual network to categorise brain tumours into one of three groups. Dense network and softmax layer compose ResNet V2's output layer. The suggested model improves the accuracy of diagnosing brain tumours. The algorithm was put to the test on a public dataset consisting of 3064 images of brain tumour imaging. The suggested model is 99.69% more effective than the best existing methods.

Brain tumour MRI images were categorised using transfer learning in ref. [14]. VGG16, ResNet50, DenseNet, and VGG19 can all identify common brain cancers with the help of transfer learning. The Figshare dataset is used to train and evaluate deep transfer learning algorithms; it consists of 3064 T1-weighted MRI scans from 233 patients with three prevalent types of brain tumours: glioma (1426 images), pituitary tumour (930 images), and meningioma (930 images) (708 photos). The model has a 99.02% improvement over ResNet50 and Adadelta.

With the RCNN method in mind, a novel framework for classifying brain tumours was developed and evaluated using two public datasets available on Figshare and Kaggle [16]. This rapid RCNN brain tumour detection was made possible by employing a low-complexity design. As a first step, the identification of glioma and healthy tumours in MRI images was enhanced by 98.21% when a Two-Channel CNN (a low-complexity framework) was used. After the Glioma MRI dataset is classified, this approach is used as a feature extractor in an RCNN to locate tumours. The tumour is surrounded by boxes. Pituitary and meningioma tumours employ this strategy as well. In a 98.8 percent confidence interval, their technique outperformed the best existing options.

III. PROPOSED METHOD

Automated tumour segmentation and MR imaging Brain tumour removal is extremely difficult. Image processing improves clarity before feature extraction, segmentation, and classification. Image analysis for brain tumour detection and segmentation includes pre-processing, segmentation, feature extraction, and categorization.

Preprocessing: The framework gets the MR brain image first. Then Pre-processing improves MR image properties for analysis. Pre-processing includes skull stripping, filtering, and morphological processes.

Brain MR images are used to derive shape, texture, and intensity information for brain tumour detection. Features are identified using Gabor, Wavelet, Spectral Mixture Analysis, Fourier, and Co-occurrence Matrix methods.

When building a model, you must narrow down a big pool of variables and predictors. The genetic algorithm, SBS, SFS, and PSO are popular methods for feature selection (PSO).

Reducing: Dimensionality reduction transforms data from a high-dimensional space to a low-dimensional space while preserving essential features, ideally in a representation near the data's vital dimension. Dimensionality reduction methods include PCA, KPCA, ICA, and linear discriminant analysis (LDA).

Segmentation methods can identify abnormalities in an image by analysing its size, volume, location, texture, and shape.

Classification involves grouping data pieces or observation values. First, an automated CAD system must categorise biomedical images. After segmentation and detection, an MRI scan's tumour status and normality were found.

3.1 Pre Processing

Image Augmentation begins preparation. Image augmentation creates similar-classed photos from a training dataset. Expansion avoids overfitting. The model needs a big data set. Image augmentation improves model efficiency. Images were flipped, shifted, and moved. Grayscale conversion follows enhancement. The Gaussian Blur filter smooths photos using the Gaussian function in the third step. This filter removes image fuzz.

3.2 Classification

Preprocessed photos are segmented. Thresholding segments this. Thresholding simplifies visual analysis. Thresholding is a common segmentation method. Binary thresholding segments. Each pixel receives the same binary cutoff value. Pixel intensity values below the cutoff are set to 0 (black), otherwise to 255. (white).

3.3 Characterization

Feature extraction follows. Feature extraction helps find the best feature in big data sets by selecting and combining variables. It lowers redundant data, making it easier for machines to build a model and speeding up learning. We're extracting features from brain MRI data using morphological techniques.

3.4 Grouping

Feature extraction divides the sample into training and testing. We saved a model from the training set. Convolutional Neural Network models. Our CNN classifies. A model can identify brain MRI images as normal or abnormal after being fed a testing set.

3.5 Convolution Neural Network

convolution Convolution, Max-Pooling, Flatten, and Thick layers were used. 240*240 photos with 2*2 zeropadding are input. Zeropadding preserves features on the edge of the source image matrix to control the output feature map size. First convolution layer receives image. The first convolution layer uses a 3*3 kernel with 64 filters. Padding makes the first convolution layer's result 242*242. First convolution layer values are 1792. The model learns faster and performs better with the ReLU activation function. Max-pooling receives activation function output. 64 filters create a 121*121 max-pooling layer image. The second convolution layer receives max-pooling layer output. This 64-filter convolution layer creates a 119*119-pixel image with a 3*3 kernel size. Parameters: 36928. ReLU is used. Max-pooling receives the final image. 64 filters in the max-pooling layer produce a 59*59 image for the third convolution layer. Third convolution layer with 3*3 kernel size and 64 filters. This layer produces a 36928-parameter 57*57 image. ReLU activation follows. A 64-filter max-pooling layer made the image 57*57. To avoid overfitting, we add a dropout layer.

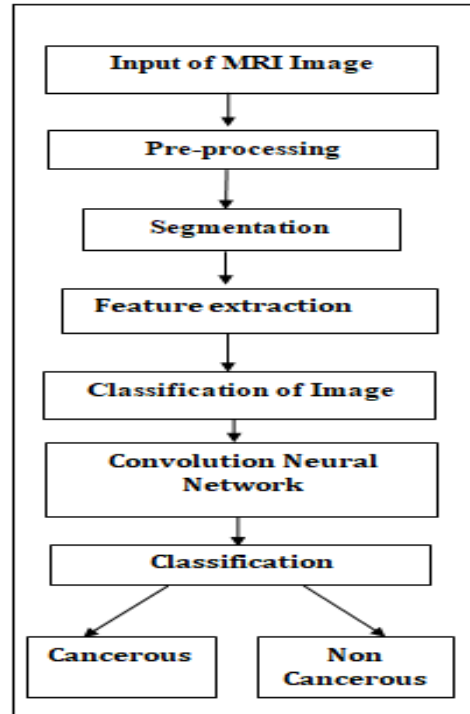


Fig.1. Basic Work Flow of Proposed System

Figure 1 depicts the proposed system's simplified process flow. Structure receives head MRI. Preprocessing, segmentation, feature extraction, and classification determine a brain MRI's normality.

Dropout randomly ignores neurons during training in Fig.2. The forward pathway deactivates selected neurons [3]. 25% of neurons were deleted. A smooth layer followed. It outputs a 1-dimensional grid from the max-pooling layer to the next layer. Flattening convolution layer output creates a linear Vector. The classification model's output comes from the flatten layer and fully linked layers [4]. Our smooth layer vector is 50179. Three thick layers followed flattening the convolution layer output. Dense layers have all neurons linked to the next layer. It includes the prior layer's feature combinations. The first thick layer yields 16 units, while the second yields 8. The output layer has 9 units/classes. The first two dense levels used ReLU. ReLU is the most common neural network triggered function. ReLU is better than sigmoid and tanh because it trains faster without losing accuracy. The final thick layer output activation function was the sigmoid function. Because the sigmoid function helps model chance outputs in fig.3.

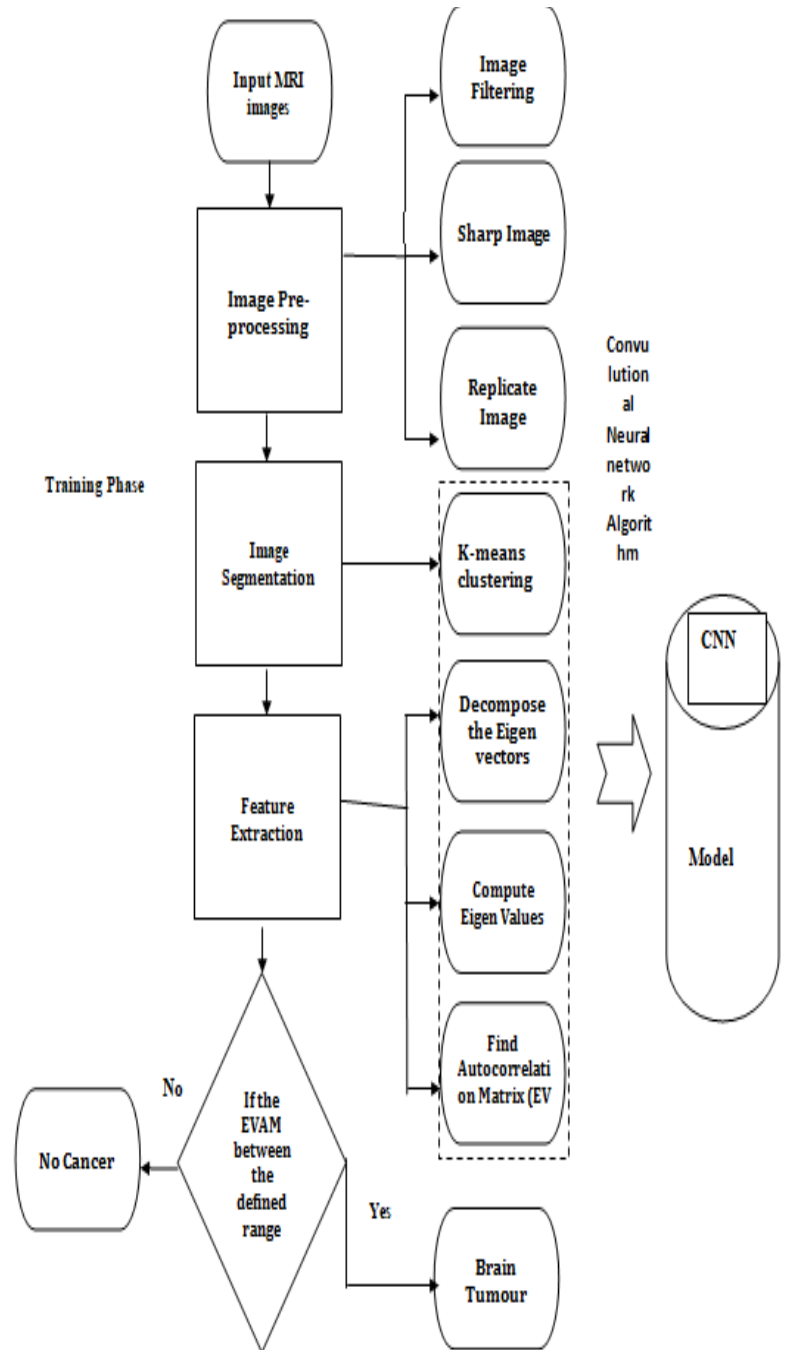


Fig. 2. Training Phase of block diagram

IV. RESULTS AND DISCUSSION

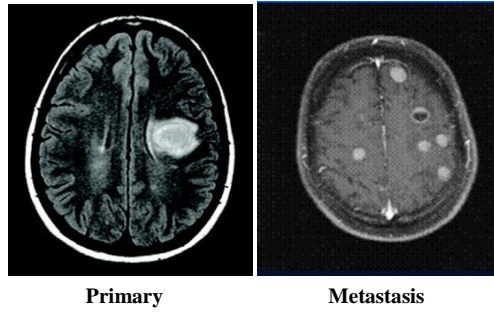


Fig. 3. Brain primary and metastasis tumor.

Table 1. Different Datasets and Their Accuracy.

No	Dataset	Accuracy
1	Dataset 1 (100 images)	98.50%
2	Dataset 2 (100 images)	87%
3	Dataset 3 (100 images)	88%
4	Dataset 4 (100 images)	85%
5	Dataset 5 (100 images)	79%
6	Dataset 6 (100 images)	80%
7	Dataset 7 (100 images)	83.23%

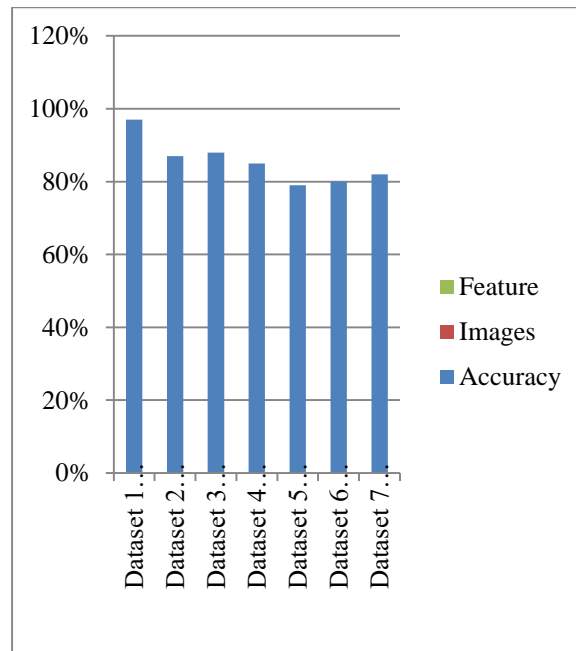


Fig.4. Different Datasets and Their Accuracy.

V CONCLUSION

In table 1 and Fig.4. We segment MR tumours in this research . The raw MRI is augmented and filtered to improve clarity. A binary trigger divides the brain tumour. Third, feature extraction uses structural processes. A classification method uses retrieved images. MRI scans are normal or aberrant. This study found that CNN detects brain tumours more accurately and efficiently than FCM, K-means, Naive Bays, SVM, and others. Analyzing Data The Kaggle dataset trains the Convolution Neural Network to divide brain tumours in MRI. The sample has 255 images: 155 brain tumour images and 98 healthy brain images. The dataset's CNN model yields 98.50% training accuracy and 83.45% validation accuracy.

References

- 1.Park JG, Lee C : Skull stripping based on region growing for magnetic resonance brain images. *Neuroimage* 47:1394–1407,(2009).
- 2.Khan MA, Lali IU, Rehman A, Ishaq M, Sharif M, Saba T et al :Brain tumor detection and classification: A framework of marker-based watershed algorithm and multilevel priority features selection. *Microsc Res Tech* 82:909–922, (2019).
- 3.Raza M, Sharif M, Yasmin M, Masood S, Mohsin S :Brain image representation and rendering: a survey. *Res J Appl Sci Eng Technol* 4:3274–3282,(2012).
- 4.Watson C, Kirkcaldie M, Paxinos G :The brain: an introduction to functional

- neuroanatomy. Academic Press, New York, (2010) .
5. Amin J, Sharif M, Anjum MA, Raza M, Bukhari SAC :Convolutional neural network with batch normalization for glioma and stroke lesion detection using MRI. *Cogn Syst Res* 59:304–311, (2020)
 6. Dubin MW :How the brain works. Wiley, New York ,(2013)
 7. Koziol LF, Budding DE, Chidekel D :From movement to thought: executive function, embodied cognition, and the cerebellum. *Cerebellum* 11:505–525, (2012)
 8. Knierim J :Neuroscience Online Chapter 5: Cerebellum. The University of Texas Health Science Center, Houston , (1997)
 9. Nuñez MA, Miranda JCF, de Oliveira E, Rubino PA, Voscoboinik S, Recalde R et al :Brain stem anatomy and surgical approaches. *Comprehensive overview of modern surgical approaches to intrinsic brain tumors*. Elsevier, Amsterdam, pp 53–105, (2019)
 10. DeAngelis LM :Brain tumors. *N Engl J Med* 344:114–123,(2001)
 11. Amin J, Sharif M, Raza M, Saba T, Sial R, Shad SA:Brain tumor detection: a long short-term memory (LSTM)-based learning model. *Neural Comput Appl* 32:15965–15973, (2020) .
 12. Sajjad S, Hanan Abdullah A, Sharif M, Mohsin S :Psychotherapy through video game to target illness related problematic behaviors of children with brain tumor. *Curr Med Imaging* 10:62–72 , (2014).
 13. Yasmin M, Sharif M, Masood S, Raza M, Mohsin S :Brain image reconstruction: a short survey. *World Appl Sci J* 19:52–62, (2012).
 14. Amin J, Sharif M, Raza M, Yasmin M :Detection of brain tumor based on features fusion and machine learning. *J Ambient Intell Human Comput*:1–17,(2018)
 15. Chen H, Zou Q, Wang Q :Clinical manifestations of ultrasonic virtual reality in the diagnosis and treatment of cardiovascular diseases. *J Healthc Eng* 2021:1–12 ,(2021).